

***Limnotrachelobdella sinensis*, a leech associated with mortality in a wild population of Japanese crucian carp *Carassius cuvieri* in Korea**

Kazuya NAGASAWA¹⁾, Sung-Woo PARK²⁾, Young-Gill KIM²⁾, and Hyoung Jun KIM³⁾

¹⁾ Graduate School of Biosphere Science, Hiroshima University
1-4-4 Kagamiyama, Higashi-Hiroshima, Hiroshima 739-8528, Japan

²⁾ Department of Aquatic Life Medicine, College of Ocean and Technology
Kunsan National University, Kunsan, Jeollabuk-do 573-701, Korea

³⁾ Fisheries Science Institute, Kunsan National University
Kunsan, Jeollabuk-do 573-701, Korea

Abstract Mortality occurred in Japanese crucian carp *Carassius cuvieri* in a reservoir in Chungnam Province, Korea, in March 2002. Moribund fish showed severe anemia in the gills and piscicolid leeches that were identified as *Trachelobdella* sp. were reported as the cause of the mortality. Re-examination of the preserved leech specimens reveals that they are not *Trachelobdella* sp. but *Limnotrachelobdella sinensis*. The external morphology of the specimens is described. This finding represents the second record of *L. sinensis* in Korea. The impact of infestation by *L. sinensis* on a host is discussed in relation to fish mortality.

Key words: *Limnotrachelobdella sinensis*, *Carassius cuvieri*, Piscicolidae, fish leech, fish parasite, fish mortality

INTRODUCTION

In March 2002, mortality occurred in a population of Japanese crucian carp (*Carassius cuvieri*) in a reservoir in Chungnam Province, Korea. Moribund fish were emaciated and showed severe anemia in the gills. As the cause of the mortality, piscicolid leeches were recovered from the gill cavity of the fish and identified as *Trachelobdella* sp. (Park and Kim, 2002). Re-examination of the specimens, however, has revealed that they are not *Trachelobdella* sp. but *Limnotrachelobdella sinensis* (Blanchard, 1896). In Korea, only one paper was published about *L. sinensis* (as *Trachelobdella sinensis*): it was found on common carp (*Cyprinus carpio*) (as Israel carp *C. carpio nudus*) cultured at a fish farm in Chuncheon (as Choonsung), Gangwon Province (Rhee, 1986). The present note reports on the morphology of the specimens, as *L. sinensis* was poorly described in Korea, and discusses the impact of leech infestation on a fish host.

MATERIALS AND METHODS

Four fish were sampled in a reservoir for agriculture (36°36'N, 126°48'E) in Yesan County, Chungnam Province, Korea on March 21, 2002. The fish were brought on ice to the laboratory of Kunsan National University, where they were measured and examined for parasites. Leeches were fixed in 40%

ethanol without relaxed and later preserved in 70% ethanol. Nine preserved specimens of these leeches were transferred to Hiroshima University, Japan, where they were identified, measured and illustrated. Four voucher specimens are deposited in the annelid (An) collection of the National Museum of Science and Technology, Tokyo (NSMT-An 403) and five specimens remain in the junior author's (HJK) collection. Intensity of infestation is defined as the number of parasites found on each host.

RESULTS

All the four fish [18.5–23.0 (mean 21.5) cm in body length] were infested by *L. sinensis*. Intensity ranged from 3 to 5 (mean 4). All leeches were firmly attached by the caudal sucker to the inner surface of the operculum and their anterior body including the oral sucker was protruded from the host's gill cavity. There were two or three round wounds (ca. 9 mm diameter) on the outer surface of the operculum.

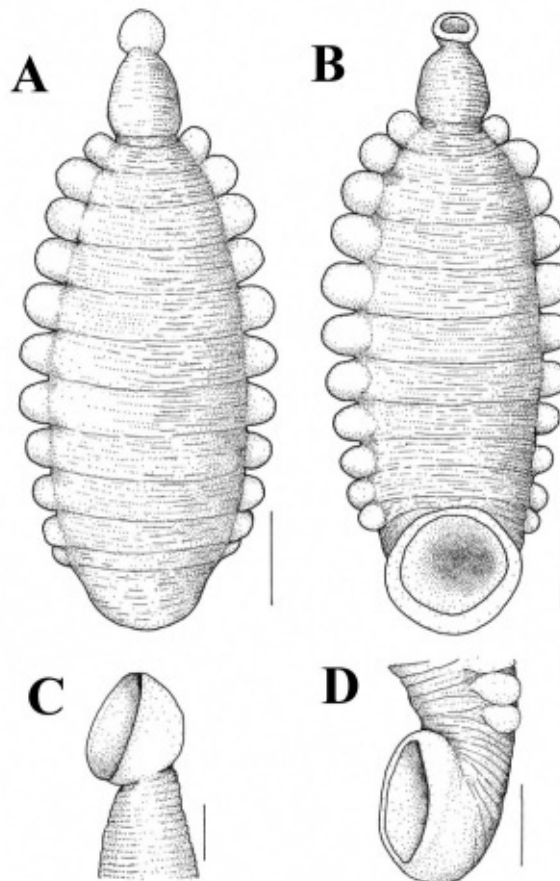


Fig. 1. *Limnotrachelobdella sinensis* from the gill cavity of Japanese crucian carp (*Carassius cuvieri*) in a reservoir in Chungnam Province, Korea. A. Entire body, dorsal view. B. Entire body, ventral view. C. Oral sucker and anterior part of trachelosome, lateral view. D. Caudal sucker and posterior part of urosome, lateral view. Scale bars = 4 mm in Figs. 1A-1B, 1 mm in Fig. 1C, and 3 mm in Fig. 1D.

Leech specimens (N=9) are 19.0-32.2 (mean 27.4) mm in total length (including the suckers) and 6.9-13.0 (10.2) mm in maximum body width. The body is obviously divided into the trachelosome and the much longer and wider urosome (Fig. 1A-1B). The body surface is weakly wrinkled. The trachelosome is slightly dorsoventrally flattened and tapers toward the oral sucker. The urosome is more dorsoventrally flattened than the trachelosome and 11 pairs of pulsatile vesicles are obvious on its lateral margins. Eye spots are invisible on the oral sucker because pigmentation has faded due to long preservation in alcohol. The oral sucker, with a diameter of 1.1-2.2 (1.7) mm, is deeply cupped and faces anteroventrally (Fig. 1C). The caudal sucker is much larger [3.5-6.0 (5.1) mm in diameter] than the oral sucker, deeply cupped with muscular rim and faces ventrally or sometimes posteriorly (Fig. 1D). Color in fresh was reddish brown (gorged specimens before fixation) but is pale yellow in alcohol.

DISCUSSION

The external morphology of the specimens observed in this study is identical with that of *L. sinensis* previously described (Yang, 1987, 1996; Lukin, 1976; Epshtein, 1987; Ogawa *et al.*, 2007; Nagasawa and Tanaka, 2009). The body shape and the presence of 11 pairs of lateral pulsatile vesicles are typical and characteristic, making the specimens easy to identify. The species is found in Far East Asia, including China (Blanchard, 1896; Moore, 1924; Chen, 1962; Yang, 1987, 1996), Russia (Lukin, 1976; Epshtein, 1987), Korea (Rhee, 1986) and Japan (Ogawa *et al.*, 2007; Nagasawa *et al.*, 2008; Nagasawa and Tanaka, 2009). The known hosts are all cyprinids: common carp, Amur carp (*Cyprinus carpio haematopterus*), Japanese crucian carp, silver crucian carp (*Carassius auratus langsdorffii*) and Prucian carp (*C. auratus gibelio*). In Korea, there is only one report about *L. sinensis* from common carp (as Israel carp) (Rhee, 1986) and our finding represents the second record of the leech in this country.

The fish examined were each infested by three to five leeches which were as big as 19.0-32.2 mm in total length. When sampled, these leeches were reddish brown in color, suggesting that they were actively feeding on the host blood. More recently in Japan, two species of crucian carps (*C. cuvieri* and *C. auratus langsdorffii*) from the Yodo River were found infested by *L. sinensis* and similarly exhibited anemia in the gills (Ogawa *et al.*, 2007). As has been suggested by Park and Kim (2002), these observations may imply that the blood feeding of *L. sinensis* can induce anemia and even mortality in its hosts. However, it is not easy to exactly assess the effects of *L. sinensis* on a fish host because only four fish were examined in this study. We need much information on the host and the leech to discern a true cause of fish mortality associated with leech infestation. Experimental study, including hematological and histological analysis, using fish of various sizes infested by different intensities of leeches, is desired to assess effects of *L. sinensis* on a host.

Limnotrachelobdella sinensis has been reported to infest fish hosts during the winter and spring months in China (Yang, 1987, 1996) and Japan (Ogawa *et al.*, 2007). At our study site in Korea, fish mortality associated with *L. sinensis* started in March 2002 and continued until mid-May 2002. In Korea, leeches were found on common carp in April 1986 (Rhee, 1986). These indicate that, similarly as in China and Japan, *L. sinensis* occurs on fishes during a limited period of the year, especially spring, in Korea. Although the life history of *L. sinensis*, in particular its early stage, is unknown, the species is estimated to have a one-year life cycle in Japan: it infests on fishes from December to April but spends other months as a non-parasitic form (including cocoons) (Ogawa *et al.*, 2007).

Limnotrachelobdella sinensis is known to infest farmed common carp in China (Yang, 1986) and Korea (Rhee, 1986). Common carp are one of the important freshwater fishes in these countries and Japan.

Crucian carps that also serve as hosts for *L. sinensis* are not usually farmed but important for recreational fishing and as food for local persons. While much needs to be studied of the pathogenicity of the leech, it is definitely an important pathogenic parasite of these cyprinids in Far East Asia. Since our knowledge of *L. sinensis* is quite limited, we need more research on its biology, including prevention and control measures to be used at fish farms.

ACKNOWLEDGMENTS

Part of this work received financial support from the Japan Society for the Promotion of Science (No. 20658046 for the Exploratory Research) and the Fisheries Science Institute of Kunsan National University.

REFERENCES

- Blanchard, R., 1896. Description de quelques Hirudinées asiatiques. *Mémoires de la Société zoologique de France*, **9**: 316-330.
- Burreson, E. M., 2006. Phylum Annelida: Hirudinea as vectors and disease agents. In: Fish Diseases and Disorders, Vol. 1. Protozoan and Metazoan Infections. 2nd ed. (ed. by P. T. K. Woo), CAB International, Oxfordshire, U.K.: 566-591.
- Chen, Y., 1962. An account of the leeches found in Nanking and vicinity with description of a new species, *Placobdella sinensis*. *Acta Zoologica Sinica*, **14**: 515-524. (In Chinese with English abstract).
- Epshtein, V. M., 1987. The Phylum Annelida. In: Identification Key to Parasites of the Freshwater Fishes of the U.S.S.R., Vol. 3. Metazoan Parasites, Part 2 (ed. by O. N. Bauer), Nauka, Leningrad, U.S.S.R.: 340-372. (In Russian).
- Lukin, E. I., 1976. Fauna of the U.S.S.R. Leeches. Vol. 1. Leeches of Fresh and Brackish Water. Nauka, Leningrad, U.S.S.R. 484 pp. (In Russian.)
- Moore, J. P., 1924. Notes on some Asiatic leeches (Hirudinea) principally from China, Kashmir, and British India. *Proceedings of the Academy of Natural Sciences of Philadelphia*, **76**: 343-388.
- Nagasawa, K., Tanaka, M., 2009. The fish leech *Limnotrachelobdella sinensis* (Hirudinida, Piscicolidae) invaded Kyoto Prefecture, central Japan. *Biogeography*, **11**: 17-21.
- Nagasawa, K., Yamauchi, T., Umino, T., 2008. Synopsis of leeches of the families Piscicolidae and Ozobranchidae (Annelida, Rhynchobdellida) in Japan (1895-2008). *Bulletin of the Biogeographical Society of Japan*, **63**: 151-171. (In Japanese with English abstract).
- Ogawa, K., Rusinek, O., Tanaka, M., 2007. New record of the leech *Limnotrachelobdella sinensis* infecting freshwater fish from Japanese waters. *Fish Pathology*, **42**: 85-89.
- Park, S.-W., Kim, Y.-G., 2002. The case report on the leech, *Trachelobdella* sp. infestation in wild crucian carp (*Carassius cuvieri*) of Chungnam Province in Korea. *Journal of Fish Pathology*, **15**: 117-119. (In Korean with English abstract).
- Rhee, J. K., 1986. *Trachelobdella sinensis* Blanchard, 1896 found from *Cyprinus carpio nudus* in Korea. *Korean Journal of Parasitology*, **24**: 216-217.
- Yang, T., 1987. On the genus *Limnotrachelobdella* Epshtein, 1968 and a new species from South China Sea. *Acta Hydrobiologica Sinica*, **11**: 268-273 (In Chinese with English abstract).
- Yang, T., 1996. Fauna Sinica. Annelida. Hirudinea. Science Press, Beijing, China. 261 pp. (In Chinese with English abstract).

韓国産野生ゲンゴロウブナの斃死に関与したマミズヒダビル

長澤和也¹⁾・朴 性佑²⁾・金 榮吉²⁾・金 亨竣³⁾

¹⁾ 広島大学大学院生物圏科学研究科, 〒739-8528 東広島市鏡山1-4-1

²⁾ 群山大学校海洋科学大学水産生命医学科, 〒7573-701 大韓民国群山市

³⁾ 群山大学校水産科学研究所, 〒7573-701 大韓民国群山市

要 旨 2002年に韓国忠清南道にある溜池でゲンゴロウブナに斃死が発生し、衰弱魚はカザリビル属の1種の寄生を受け鰓に著しい貧血症状が見られたため、このヒルが斃死原因であると報告された。今回、そのときに採集されたヒル標本を観察した結果、それらはカザリビル属ではなくヒダビル属のマミズヒダビル*Limnotrachelobdella sinensis*に同定された。本論文では、その外部形態を記載した。これは韓国における本虫の2度目の発見であり、ゲンゴロウブナは同国における新宿主である。宿主の斃死との関連でマミズヒダビルの病害性を議論した。

キーワード：マミズヒダビル, ゲンゴロウブナ, ウオビル類, 魚類寄生虫, 魚類斃死